

Kelly (H. A.)

A DEATH CAUSED BY A  
UTERINE DILATOR,

WITH SOME REMARKS AS TO THE PROPER  
METHOD OF USING THE DILATOR.

BY

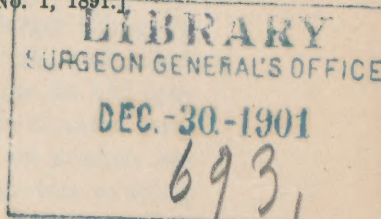
HOWARD A. KELLY, M.D.,

Professor of Gynecology in the Johns Hopkins University ; Gynecologist and Obstetri-  
cian to the Johns Hopkins University,  
Baltimore, Md.

---

[Reprinted from the AMERICAN JOURNAL OF OBSTETRICS AND DISEASES  
OF WOMEN AND CHILDREN, Vol. XXIV., No. 1, 1891.]

---



NEW YORK :  
WILLIAM WOOD & COMPANY, PUBLISHERS,  
56 & 58 LAFAYETTE PLACE.  
1891.

THE BERRY-BELLATOR

WITH SOME REMARKS AS TO THE PROPER  
METHOD OF PAID THE PLOTTER

HOW AND A. BELLATOR

THE BERRY-BELLATOR

THE BERRY-BELLATOR

1911  
1911  
1911

THE BERRY-BELLATOR

THE BERRY-BELLATOR

A DEATH CAUSED BY A  
UTERINE DILATOR,

WITH SOME REMARKS AS TO THE PROPER  
METHOD OF USING THE DILATOR.

---

THE uterine dilator has now grown to be an instrument of such common use that a word of caution as to possible dangers will not be unseasonable. About three years ago a physician who has since died, a man also of considerable local repute as a surgeon, called at my house and borrowed two dilators. He took one called Wilson's, a slight instrument with a very strong curve, tapering to a small point, and a larger Ellinger's dilator. About four days later he returned them, and called me in consultation to see the person upon whom he had operated. I found a slight young woman with an elevated temperature, and a small, quick pulse. She had an anxious expression, a dry tongue, and a fetid discharge was exuding from the vagina. Upon lifting her on to a table and exposing the cervix, I discovered a square, friable, rotten, black sponge, about two inches long, projecting from the os externum, through which I removed it in small pieces. It was the remains of a sponge tent made of the coarse material commonly used for washing out the mouths of horses.

About  $1\frac{1}{2}$  cm. ( $+\frac{1}{2}$  in.) above the os externum, in the posterior wall of the uterus, was a rent, 2 cm. in length, through which the finger passed into the peritoneal cavity, from which I had removed a part of the stinking sponge. The uterine body above was slightly enlarged from a pregnancy interrupted in the third month. The woman was clearly suffering from septic peritonitis consequent upon the perforation of the posterior wall of the cervix in attempting to introduce a sharp-pointed dilator into an anteflexed uterus (see Fig. 1). The small hole made by the point of the dilator had been more widely torn open by the larger instrument, and this was followed by the insertion of the sponge tents through the hole into the peritoneal cavity, thus insuring the infection of the abdominal cavity.

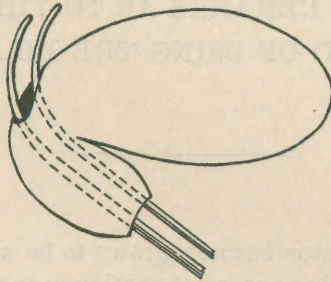


FIG. 1.

My urgent advice was immediate laparotomy, for the purpose of cleansing the peritoneal cavity, closing the rent, and draining the abdomen; but this the physician would not consent to, as he felt sure that the patient's condition could not be very serious, as she was suffering so little pain! Five days later, however, he called upon me in the evening, when I made a long trip to the house and operated near midnight. The patient's condition this time seemed hopeless, as she lay in the bed with a cylindrical abdomen, a flickering pulse, and an apathetic stare; but with a desire to give her the faintest glimmer of a chance for life by evacuating the pus and washing out the abdomen, I made hasty preparations and operated.

Under ether anesthesia, she was placed on my ovariectomy drainage pad on a table, and the abdomen was quickly opened. Fluid gushed from the opening, and about a litre (one quart) of

fetid, bloody serum mixed with flakes of lymph was ladled out with a small tin cup. There was an extensive peritonitis, involving all of the smaller intestines, which cohered, covered with flakes of lymph (Fig. 2). The rent in the uterus was found posteriorly in the cervix, low down near the pelvic floor. Hypodermics of brandy frequently given during the short operation whipped up the flagging heart, a drainage tube was inserted, and she was put back into a warm bed, and every effort made by hypodermics of strychnia, atropia, brandy, and digitalis, and stimulating enemata, to raise her out of the profoundly shocked state in which she died four hours later.

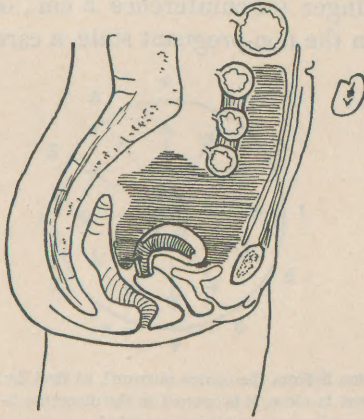


FIG. 2.

He who runs may read. The lesson taught by this awful tragedy is a plain one. The first objection is manifestly not against dilators in general, but against those dilators which end in a sharp point and are strongly curved in the dilating blades.

The liability to perforate an anteflexed uterus with such an instrument is so manifest that I cannot help thinking that this accident has occurred more than once.

A further objection is against the manner of inserting the dilator—*force should never be employed*. The practice of grasping the dilator in the full hand and forcibly punching or boring it up into the uterus, and trusting that it will find the uterine canal to be the direction of least resistance, is altogether reprehensible.

The proper way to introduce the dilator is to hold it like a pen, delicately poised in mobile equilibrium between thumb and index and second fingers; thus held, it should with gentleness be persuaded to enter the canal of the uterus, whose direction has been determined, guided onward past the internal os, and then used as a dilator.

Another point is of great importance, correcting a common error. A frequent method of dilating is by screwing together the handles of the dilator, or by means of a ratchet attachment on the handle, never relaxing, but gradually forcing the handles together until the desired degree of dilatation is obtained. When this manoeuvre is carried far enough to admit a small index finger (circumference 5 cm., or 2 in.) into the uterine cavity in the non-pregnant state, a careful examination

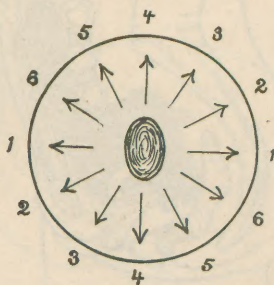


FIG. 3.—The dilatation is from the centre outward, at first in the directions 1-1; then allowing the instrument to close, it is opened in the direction 2-2, then 3-3, 4-4, 5-5, 6-6, and back again to 1-1, and so on until it is completed.

will almost always reveal a long laceration within the cervical canal, thus split on one or both sides, and occasionally throughout the whole length and thickness of the canal. This splitting of the cervix may sometimes be found when there is no evidence of any tear on the vaginal surface.

It is also well known that serious deep lacerations of the vaginal cervix are often thus brought about. A friend saw a typical vegetating cancer develop on such a lacerated cervix in a woman who had never been pregnant.

Instruments with ratchets and screw devices are on this account to be condemned.

The best dilators are simply constructed with a spring between the arms, closing the blades as soon as the dilating pressure ceases.

With such an instrument in my hand, I carefully insert it and proceed for a moment to gently dilate the canal in one direction, then, relaxing the pressure, the blades close and the dilator is rotated a little, again gently dilating another portion of the canal, and so on all around the circle and back to the first point, and around again, until the cervix, softened by these repeated gentle impacts from within on all sides, gradually and equably yields to the necessary extent without any laceration.

